jove | Medicine

DATE PUBLISHED November 20, 2026
DOI 10.3791/73227
URL jove.com/t/73227

Appositional White Adipose Tissue Transplantation in Mice: A Method for Preserving Graft Architecture and Promoting Donor–Host Integration

Xin Li[1], **Shiuhwei Chen**[1], **Philipp E Scherer**[1]

[1]Touchstone Diabetes Center, The University of Texas Southwestern Medical Center

Corresponding Author : Philipp E Scherer <philipp.scherer@utsouthwestern.edu>

Citation

Li, X., Chen, S., Scherer, P.E. Appositional White Adipose Tissue Transplantation in Mice: A Method for Preserving Graft Architecture and Promoting Donor–Host Integration. *J. Vis. Exp.* (237), e73227, doi:10.3791/73227. (2026).

Abstract

Adipose tissue transplantation is a widely used experimental approach for investigating depot-specific adipose biology and determining how donor adipose tissue influences local and systemic metabolism in recipient mice. Existing transplantation methods include fat-slice implantation, fragment transplantation, and syringe-assisted delivery, each of which has distinct experimental features. The appositional approach described here was developed and validated in male mice to maintain the donor adipose tissue as an intact graft, provide controlled graft positioning, and establish a defined area of direct contact between donor and recipient adipose tissues.

Here, we describe an appositional adipose tissue transplantation protocol in which an intact donor white adipose tissue graft (~200 mg) is positioned directly against the corresponding endogenous epididymal or inguinal white adipose tissue depot in the male recipient mouse. The donor and recipient tissue surfaces are gently prepared with 10–12 shallow micro-scissor incisions and secured together using 5/0 absorbable polyglycolic acid (PGA) sutures. This design maintains the donor graft as a single tissue unit and establishes stable adipose-to-adipose contact while avoiding excessive compression of the apposed tissues.

The protocol incorporates complementary approaches to evaluate the transplanted tissue and donor–recipient interface. For the interface analysis, the donor graft and adjacent recipient adipose tissue are collected together as an intact tissue block and processed for frozen sectioning to directly visualize the interface. Using Rosa26-mT/mG reporter mice as donors allows distinction between donor and recipient tissues based on reporter fluorescence, while bright-field imaging and subsequent hematoxylin and eosin (H&E) staining of the same sections provide complementary morphological assessment of the interface. In separate transplantation experiments used for vascular and neural assessment, fluorescent Lectin 594 is administered intravenously to label vessels perfused through the recipient circulation. Donor grafts and recipient adipose tissues are subsequently analyzed using whole-mount immunofluorescence staining for CD31-positive vascular structures and tyrosine hydroxylase (TH)-positive sympathetic nerve fibers. Together, these approaches allow assessment of the donor–recipient interface, vascular

Copyright © 2026, Journal of Visualized Experiments

DOI 10.3791/73227

structures, functional vascular perfusion, and the presence of sympathetic nerve fibers, providing an experimental platform for studying adipose tissue integration, remodeling, angiogenesis, innervation, and donor–host adipose interactions *in vivo*.

Introduction

White adipose tissue is not merely an energy storage depot but also an endocrine and immunologically active organ that regulates glucose homeostasis, insulin sensitivity, inflammation, and systemic energy balance[1,2]. Distinct white adipose depots exhibit unique developmental, metabolic, and inflammatory characteristics. These depot-specific features make adipose tissue transplantation a valuable experimental strategy for determining whether donor fat depots can confer local or systemic metabolic effects to recipient mice[3].

Adipose tissue transplantation has therefore been widely used to investigate depot-specific adipose function and determine whether distinct fat depots can influence recipient physiology. In a seminal study, subcutaneous or epididymal adipose tissue from C57BL/6 donor mice was transplanted into either the subcutaneous or visceral compartment of recipient mice, allowing independent assessment of donor depot identity and recipient anatomical location. These experiments demonstrated that transplanted adipose tissue can exert significant systemic metabolic effects, including alterations in body weight, adiposity, glucose tolerance, and insulin sensitivity, establishing adipose transplantation as a powerful tool for studying adipose tissue biology and metabolic regulation[4].

Several adipose tissue transplantation approaches have been developed, including whole-depot transfer, fat-slice implantation, small-fragment transplantation, and needle- or syringe-assisted delivery methods. Although each approach offers distinct experimental advantages, they differ in their ability to preserve tissue architecture, control graft positioning, and maintain consistent donor–host interactions[5,6,7,8]. These methods are well-suited for a range of experimental applications. Syringe-assisted delivery can reduce operative time and minimize graft ischemia, whereas slice- and fragment-based approaches increase graft surface area and may mitigate central ischemia in larger grafts. However, these techniques can also disrupt native adipose tissue architecture and introduce variability in graft positioning and donor–host interactions[6].

Despite their advantages, existing transplantation methods have important limitations. Mechanical cutting, mincing, homogenization, and syringe passage can damage fragile mature adipocytes and disrupt the native architecture of adipose tissue, including its extracellular matrix, vascular scaffold, stromal compartment, and immune cell organization. As a result, these approaches may alter the biological properties of the graft and complicate the interpretation of donor-derived effects after transplantation[9]. In slice-based implantation approaches, donor adipose tissue is divided into multiple pieces and implanted into recipient tissue spaces. Although this strategy increases graft surface area and may reduce central ischemia, individual graft fragments can be difficult to maintain in a consistent anatomical position. Consequently, graft orientation, donor–host contact area, and local tissue interactions may vary between animals, introducing experimental variability and limiting precise control over graft-host integration.

To address these limitations, we developed a standardized appositional adipose tissue transplantation method that preserves donor tissue architecture while establishing direct and stable donor–host contact. In this protocol, donor adipose tissue is transplanted as an intact graft of approximately 200 mg rather than as a homogenized preparation or multiple small fragments. The method can be used for both epididymal white adipose tissue-to-epididymal white adipose tissue and inguinal white adipose tissue-to-inguinal white adipose tissue transplantation. To promote graft integration, the opposing surfaces of the donor graft and recipient adipose pad are gently prepared with shallow micro-scissor incisions. The donor graft is then apposed directly onto the prepared recipient adipose surface and secured using 5/0 absorbable polyglycolic acid (PGA) sutures, ensuring stable adipose-to-adipose contact while minimizing tissue compression and structural disruption.

This approach preserves native adipose tissue architecture, standardizes graft size, and establishes stable adipose-to-adipose contact between donor and recipient tissues. Compared with slice-based implantation methods, appositional transplantation is designed to provide controlled graft positioning, orientation, and donor–host contact, with the aim of improving experimental reproducibility. By promoting close tissue apposition, the method is designed to facilitate early tissue fusion, vascular remodeling, and long-term graft preservation. The protocol also incorporates Lectin 594 perfusion and modified whole-mount adipose tissue immunofluorescence staining for CD31 and tyrosine hydroxylase (TH) to evaluate vascular structure, functional vascular perfusion through the recipient circulation, and sympathetic nerve fiber presence following transplantation. As such, this method is well suited for studies of adipose tissue remodeling, angiogenesis, inflammation, fibrosis, vascular integration, innervation, and depot-specific adipose signaling. Overall, appositional adipose tissue transplantation provides a reproducible and physiologically

Copyright © 2026, Journal of Visualized Experiments

DOI 10.3791/73227

relevant platform for investigating adipose graft integration and donor–host tissue interactions *in vivo*.

Protocol

The procedure outlined here has been approved by the Institutional Animal Care and Use Committee (IACUC) of The University of Texas Southwestern Medical Center under protocol number APN 2024-103556.

NOTE: The general transplantation workflow was adapted from previously reported adipose tissue transplantation methods[6,7,8], whereas the present protocol introduces intact graft apposition to preserve tissue architecture and stabilize donor–host contact. All surgical instruments should be sterilized prior to surgery using a hot bead sterilizer and cleaned with 75% ethanol. All surgical procedures should be performed under aseptic conditions. Three-month-old male C57BL/6J mice were used as recipients for adipose tissue transplantation. Three-month-old male Rosa26-mT/mG mice (The Jackson Laboratory, Stock No. 007676) were used as donors. The mice weighed approximately 30 g at the time of transplantation. A total of 24 mice (12 recipients and 12 donors) were used. For the initial histological analyses, three independent experiments were performed at each postoperative time point, with one donor mouse and one recipient mouse used for postoperative day 1 and another donor–recipient pair used for postoperative day 2. Three additional independent experiments were performed using the same postoperative time points, in which the donor graft and surrounding recipient tissue were collected together for frozen-section analysis of the donor–recipient interface. All animals were housed under standard conditions with ad libitum access to food and water, a 12 h light/dark cycle, and controlled ambient temperature. Keep donor and recipient adipose tissues moist throughout the procedure using sterile PBS.

1. Preparation of donor adipose tissue

1. Anesthetize the donor mouse using inhaled isoflurane (5% for induction) and euthanize by cervical dislocation according to the approved animal protocol.
2. Place the donor mouse in the appropriate surgical position and disinfect the surgical area using alternating povidone-iodine and 75% ethanol.
    1. For epididymal white adipose tissue collection, place the mouse in dorsal recumbency and make a small lower abdominal incision through the skin and abdominal wall. Gently expose and harvest the right epididymal adipose pad while avoiding excessive pulling, squeezing, or tearing of the tissue.
    2. For inguinal white adipose tissue (iWAT) collection, place the mouse in ventral recumbency and make a small skin incision above the inguinal adipose depot. Carefully expose and harvest the right iWAT with minimal mechanical manipulation.
3. Weigh the harvested adipose pad. If the tissue weighs ≤200 mg, use the entire adipose pad as the donor graft without further trimming. If the tissue weighs >200 mg, trim the excess tissue using sterile scissors to obtain a graft of approximately 200 mg.
4. Immediately place the collected adipose tissue in sterile phosphate buffered saline (PBS) at room temperature and proceed with graft preparation and transplantation without unnecessary delay.

    NOTE: Donor adipose tissue should be maintained as an intact tissue piece prior to graft-host interface preparation. Excessive fragmentation or mechanical disruption of the graft should be avoided to preserve adipose tissue architecture. Following collection, temporarily maintain the donor tissue in sterile PBS at room temperature and proceed immediately with graft preparation and transplantation without an intentional holding period.

2. Recipient adipose tissue preparation

NOTE: All recipient procedures should be performed under aseptic conditions using sterile surgical instruments and supplies. Maintain body temperature throughout the procedure using a heating pad. Keep exposed adipose tissue moist throughout the procedure using sterile PBS.

1. Anesthetize recipient mice using inhaled isoflurane (5% for induction and 2% for maintenance throughout the surgical procedure) and apply ophthalmic ointment to prevent corneal drying during surgery.

    NOTE: The entire surgical procedure typically requires approximately 5–10 min, depending on operator experience, during which anesthesia is continuously maintained.
2. Shave the surgical area and disinfect the skin using alternating povidone-iodine and 75% ethanol.
3. Place the mouse on a sterile surgical drape positioned over a heating pad and maintain anesthesia throughout the procedure.
    1. For epididymal white adipose tissue transplantation, place the mouse in dorsal recumbency and make a 7–10 mm lower abdominal incision through the skin and abdominal wall. Gently exteriorize the entire right epididymal adipose pad and place it on sterile PBS-moistened gauze.
    2. For inguinal white adipose tissue transplantation, place the mouse in ventral recumbency and make a small skin incision above the right inguinal adipose depot. Carefully

Copyright © 2026, Journal of Visualized Experiments

DOI 10.3791/73227

expose the endogenous iWAT and place it on sterile PBS-moistened gauze.

4. Position two 5/0 absorbable PGA sutures underneath the adipose pad for subsequent graft attachment.

3. Adipose graft apposition and closure

NOTE: Maintain both donor and recipient adipose tissues moist throughout the procedure using sterile PBS. Avoid excessive tissue injury or disruption of major blood vessels during interface preparation.

1. Position the donor adipose graft parallel to the recipient adipose pad with the intended graft surfaces facing upward.
2. Using fine micro-scissors, make 10–12 shallow incisions on the surface of both the donor and recipient adipose pads while avoiding major blood vessels. Minor bleeding may occur during interface preparation.
3. Flip the donor adipose graft and place the prepared donor surface directly against the prepared recipient adipose surface to establish direct adipose-to-adipose contact.
4. Tie the 5/0 absorbable PGA sutures securely around the combined adipose pads while avoiding excessive compression.
5. Return the combined adipose tissue to the abdominal cavity or subcutaneous space.
    1. For epididymal adipose tissue transplantation, close the abdominal wall using absorbable sutures and close the skin incision using wound clips.
    2. For inguinal white adipose tissue transplantation, close the skin incision using wound clips or absorbable sutures.

    NOTE: Excessive compression of the combined adipose pads may impair local blood circulation and reduce graft viability.

4. Postoperative care

1. Place recipient mice on a heating pad immediately after surgery until fully awake and ambulatory.
2. Administer carprofen (5 mg/kg, subcutaneously, every 24 h) and regular injectable buprenorphine (0.1 mg/kg, subcutaneously, every 6 h) for 48 h after surgery. Monitor each mouse for signs of pain.
3. Return mice to clean cages with easy access to food and water after recovery from anesthesia.
4. Monitor mice daily for wound healing, grooming behavior, mobility, body condition, and signs of distress, infection, or wound dehiscence.
5. Examine the grafted area regularly for excessive swelling, bleeding, or abnormal tissue appearance.
6. Remove wound clips 7–14 days after surgery if necessary.

5. Tissue collection, Lectin perfusion, and modified adipose tissue immunofluorescence staining

NOTE: The immunofluorescence staining procedure used in this section is adapted from a previously described adipose tissue blood vessel and nerve fiber co-staining method[10]. This method is modified here to examine vascular structures, functional vascular perfusion, and nerve fibers in transplanted donor epididymal white adipose tissue (eWAT) and endogenous recipient eWAT. Fluorescent Lectin 594 is injected into recipient mice before tissue collection to label vessels that are perfused through the recipient circulation. CD31 staining is used to identify vascular structures in the donor graft and recipient eWAT. TH staining is used to identify nerve fibers. The combined detection of CD31-positive and Lectin 594-positive vessels in the donor graft supports vascular connection between the donor graft and the recipient circulation. The presence of TH-positive nerve fibers in the donor graft supports neural preservation or remodeling after transplantation. Standard thin adipose tissue sections are not used for this analysis because thin sections do not clearly show the vascular and nerve fiber networks in adipose tissue.

1. At the selected postoperative time point, anesthetize the recipient mice using inhaled isoflurane (5% for induction) mouse according to the approved animal protocol.
2. Inject 100 µL of fluorescently labeled DyLight 594-conjugated tomato lectin (1 mg/mL) intravenously before tissue collection.
3. Allow Lectin 594 to circulate for 10 min.
4. Euthanize the anesthetized recipient mouse via cervical dislocation in accordance with the IACUC-approved animal protocol.
5. Perfuse the mouse with cold PBS to remove blood and unbound Lectin from the circulation.

    NOTE: PBS perfusion is important because residual blood can increase background fluorescence and complicate vascular imaging.
6. Carefully reopen the previous surgical site and expose the grafted adipose tissue.
7. Identify the transplanted donor eWAT, the endogenous recipient eWAT, and the donor-recipient contact region.
8. Collect the donor graft and recipient eWAT together as one connected tissue block.

Copyright © 2026, Journal of Visualized Experiments

DOI 10.3791/73227

NOTE: This step helps preserve the original graft position during dissection. It also allows the donor and recipient tissues to be identified before they are separated for fixation.

9. Place the connected tissue block in cold PBS in a Petri dish.
10. Examine the tissue under a dissecting microscope if needed. Confirm the donor graft, recipient eWAT, and the contact region.
11. Gently separate the donor graft from the recipient eWAT using fine forceps and micro-scissors.

    NOTE: Avoid squeezing or tearing the adipose tissue. Avoid cutting through large visible vessels when possible.
12. Place the donor graft and recipient eWAT into separate tubes containing freshly prepared 1% paraformaldehyde (PFA) in 1× PBS, pH 7.4.
13. Fix the tissues in 1% PFA at 4 °C for 24–48 h with gentle rocking.

    NOTE: Keep samples protected from light after Lectin 594 injection.
14. Remove the 1% PFA and wash the tissues with 1× PBS three times.
15. Trim each fixed adipose tissue sample into small, flat pieces or approximately 2-mm tissue pieces suitable for antibody penetration and fluorescence imaging.

    NOTE: Very thick adipose tissue pieces stain poorly because antibodies do not penetrate evenly. Small and flat pieces also improve imaging depth.
16. Place the trimmed adipose tissue pieces into microcentrifuge tubes or a multi-well plate.
17. Permeabilize the tissue pieces in PBS containing 1% Triton X-100 (PBS-T) at room temperature for 1 h with gentle rotation.

    NOTE: PBS-T is used for tissue permeabilization. This step improves antibody penetration into adipose tissue. Prepare PBS-T according to the previously described adipose tissue blood vessel and nerve fiber co-staining method.
18. Remove PBS-T and incubate the tissue pieces in blocking buffer containing normal goat serum (5%) at room temperature for 2 h with gentle rotation.

    NOTE: Normal goat serum is used to reduce nonspecific antibody binding. Make sure the tissue pieces are fully submerged during blocking.
19. Prepare the primary antibody solution containing anti-CD31 antibody (1:100) and anti-tyrosine hydroxylase (TH) antibody (1:200) in blocking buffer containing normal goat serum (5%).
20. Incubate the tissue pieces with primary antibodies against CD31 and TH at 4 °C for 24–48 h with gentle rotation.

    NOTE: A longer primary antibody incubation improves antibody penetration into adipose tissue. Keep samples protected from light because Lectin 594 signal is already present. CD31 is used to label vascular structures in the donor graft and recipient eWAT. TH is used to label nerve fibers in the donor graft and recipient eWAT.
21. Remove the primary antibody solution.
22. Wash the tissue pieces three times in PBS-T for 30 min per wash at room temperature with gentle rotation.

    NOTE: Adequate washing is important because adipose tissue can retain antibody solution, generating a high background signal.
23. Prepare the appropriate fluorescent secondary antibody solution in blocking buffer containing normal goat serum: donkey anti-rat Alexa Fluor 647 (1:500) for CD31 staining or donkey anti-rabbit Alexa Fluor 647 (1:500) for TH staining.
24. Incubate the tissue pieces with secondary antibodies at room temperature for 2 h with gentle rotation.

    NOTE: Protect samples from light during and after secondary antibody incubation. Choose secondary antibody fluorophores that do not overlap with Lectin 594.
25. Remove the secondary antibody solution.
26. Wash the tissue pieces three times in PBS-T for 30 min per wash at room temperature with gentle rotation.
27. Wash the tissue pieces once with 1× PBS.
28. Transfer the stained tissue pieces into 90% glycerol for optical clearing.
29. Incubate the tissue pieces in 90% glycerol overnight at 4 °C in the dark.

    NOTE: This optical clearing step improves visualization of blood vessels and nerve fibers in adipose tissue.
30. Mount the cleared adipose tissue pieces on glass slides in 90% glycerol.
31. Gently spread and flatten the tissue pieces without crushing the adipocytes.

    NOTE: Use spacers if needed to avoid compression of the adipose tissue.
32. Image the stained tissue using a fluorescence microscope or confocal microscope. Assess vascular connection by examining Lectin 594-positive and CD31-positive vessels in the donor graft. Assess sympathetic nerve fiber presence by examining TH-positive nerve fibers in the donor graft.

Copyright © 2026, Journal of Visualized Experiments

DOI 10.3791/73227

NOTE: Because the donor graft and recipient eWAT are separated before fixation, this protocol does not image the intact donor–recipient interface. Instead, donor and recipient adipose tissues are analyzed separately after the graft–host relationship is confirmed during dissection.

6. Frozen-section analysis of the donor–recipient interface

NOTE: Fluorescent reporter mice can be used as donors to facilitate distinction between donor and recipient tissues during interface analysis. In the present study, interface analysis was performed on postoperative day 2, when the donor graft and recipient adipose tissue could be collected together as an intact tissue block.

1. On postoperative day 2, collect the donor graft together with the adjacent recipient adipose tissue as a single intact tissue block. Avoid pulling, stretching, or separating the tissues at the donor–recipient interface during collection.
2. Completely immerse the intact tissue block in 4% paraformaldehyde (PFA) and fix for 24 h at 4 °C.
3. Transfer the fixed tissue block to PBS and incubate for 24 h at 4 °C.
4. Cryoprotect the tissue sequentially in 15% (w/v) sucrose for 12 h at 4 °C and then in 30% (w/v) sucrose for 24 h at 4 °C. Ensure that the tissue remains completely submerged in each solution.
5. Embed the intact tissue block in optimal cutting temperature (OCT) compound. Orient the tissue block so that sections are collected across the donor–recipient interface, with both donor and recipient adipose tissues present within the same section.
6. Prepare 20-µm-thick frozen sections using a cryostat, collect the sections onto microscope slides, and store the slides at -20 °C until imaging.
7. Before H&E staining, allow the slides to equilibrate to room temperature and acquire bright-field and fluorescence images of the unstained sections.
    1. When Rosa26-mT/mG reporter mice are used as donors, identify the donor region based on its readily distinguishable tdTomato red fluorescence above the background fluorescence present in the adjacent recipient adipose tissue.
    2. Use the fluorescence pattern together with tissue morphology to locate the donor–recipient interface.
8. After bright-field and fluorescence imaging, perform H&E staining on the same frozen sections.
    1. Rinse the sections in PBS for 5 min to remove residual OCT compound, followed by a brief rinse in distilled water.
    2. Stain the sections in hematoxylin for 5 min.
    3. Rinse the slides in running tap water for 5 min to remove excess hematoxylin and allow the nuclei to turn blue.
    4. Stain the sections in eosin for 1 min.
    5. Dehydrate the sections sequentially in 70% ethanol for 30 s, 95% ethanol for 30 s, 100% ethanol for 1 min, and fresh 100% ethanol for an additional 1 min.
    6. Clear the sections in xylene twice for 2 min each.
    7. Mount the sections using a mounting medium and apply coverslips.
9. Acquire bright-field images of the H&E-stained sections. Compare the H&E images with the bright-field and red fluorescence images acquired from the same sections before H&E staining to identify the donor tissue, recipient tissue, and donor–recipient interface.

Results

To determine the earliest stages of donor–host tissue integration following transplantation, we examined the gross morphology of the graft interface during the first two postoperative days (**Figure 1** and **Figure 2**). By day 1, donor and recipient eWAT pads exhibited visible signs of early tissue fusion (**Figure 1A**). Because the tissues were initially brought into contact by suturing, simple attachment was not considered sufficient evidence of integration. Instead, we assessed the appearance of the donor–recipient interface after tissue collection. At this time point, the donor and recipient fat pads no longer appeared as completely separate tissue structures. The boundary between the two tissues was less distinct, and a continuous tissue bridge was evident at the contact site. These observations suggest that physical integration between donor and recipient eWAT begins within 24 h of transplantation.

By day 2, donor–recipient eWAT fusion was more pronounced (**Figure 2A**). Compared with day 1, the fused region was larger, the interface appeared broader and more continuous, and the boundary between the two tissues became less distinct. Together, these findings indicate that donor and recipient eWAT undergo rapid and progressive tissue fusion within the first two days after transplantation.

To more directly distinguish donor tissue from recipient tissue and visualize the donor–recipient interface, additional transplantation experiments were performed using Rosa26-mT/mG reporter mice as donors. Interface analysis was performed on postoperative day 2, when the donor graft and adjacent recipient adipose

Copyright © 2026, Journal of Visualized Experiments

DOI 10.3791/73227

tissue could be collected together as an intact tissue block. The intact donor–recipient tissue was processed for frozen sectioning, and bright-field and fluorescence images were acquired before histological staining. Although background fluorescence was present in recipient adipose tissue, the donor tissue showed readily distinguishable tdTomato red fluorescence above the recipient background. Evaluation of the fluorescence pattern together with tissue morphology allowed the donor and recipient regions to be distinguished and the interface to be localized (**Figure 3**). The same sections were subsequently subjected to H&E staining, providing complementary morphological visualization of the donor–recipient interface. This reporter-based analysis provides an additional validation of donor–recipient tissue assignment beyond gross appearance and suture position.

We next assessed whether the donor eWAT retained vascular and sympathetic nerve structures during this early period of tissue integration.These vascular and nerve analyses were performed in separate transplantation experiments that did not use Rosa26-mT/mG reporter mice as donors. Whole-mount staining showed CD31-positive vascular structures within the donor graft at both day 1 and day 2 after transplantation (**Figure 1B** and **Figure 2B**). In addition, Lectin 594 signal was detected within vessel-like structures in donor eWAT, suggesting that graft-associated vessels were perfused through and connected to the recipient circulation. TH-positive fibers were also present within the donor graft, indicating the persistence of sympathetic nerve structures following transplantation (**Figure 1B** and **Figure 2B**).

Because early tissue fusion alone does not demonstrate long-term graft viability or stable host integration, we further examined transplanted eWAT 3 weeks after surgery. At this later time point, the graft showed evidence of sustained viability and integration with the host (**Figure 4**). CD31 staining identified endothelial structures within the graft, and Lectin 594 signal was detected in vessel-like structures, suggesting that graft-associated vessels remained perfused through and connected to the host circulation. TH-positive fibers were also present within the transplanted tissue, indicating the persistence of sympathetic nerve structures after transplantation.

Together, these findings show early and progressive physical association between donor and recipient eWAT during the first two postoperative days. Reporter-based frozen-section analysis further allowed direct distinction of the donor and recipient regions and localization of their interface on postoperative day 2. Vascular structures, perfused vessel-like structures, and TH-positive fibers were detected within the graft during the early postoperative period and remained detectable at 3 weeks after transplantation. **Figure 5** provides a schematic overview of the appositional eWAT transplantation procedure, highlighting donor graft preparation, donor–recipient surface incisions, and suture-mediated apposition. The schematic also summarizes the subsequent assessment of graft vascular perfusion, endothelial structures, and sympathetic nerve fibers using intravenous Lectin 594 labeling and CD31 and TH staining.

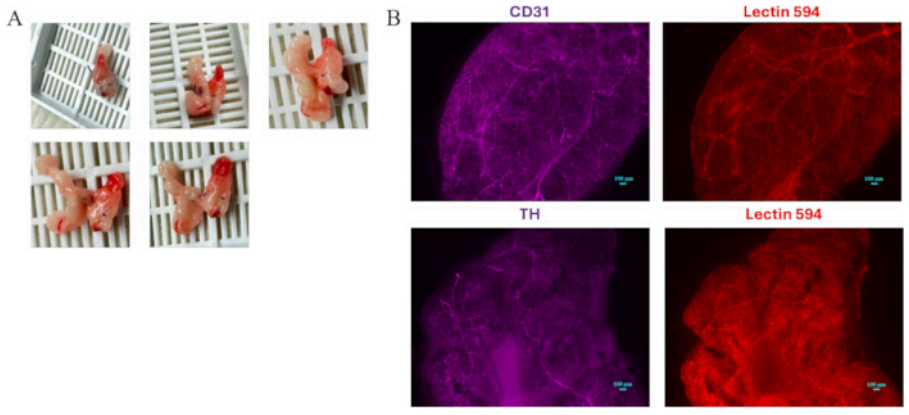

Figure 1: Donor eWAT on postoperative day 1. Representative images of transplanted eWAT collected 1 day after transplantation. (**A**) Representative images of the recovered transplanted tissue at the time of collection. (**B**) Representative images of donor eWAT stained for CD31, Lectin 594, and TH. Please click here to view a larger version of this figure.

Copyright © 2026, Journal of Visualized Experiments

DOI 10.3791/73227

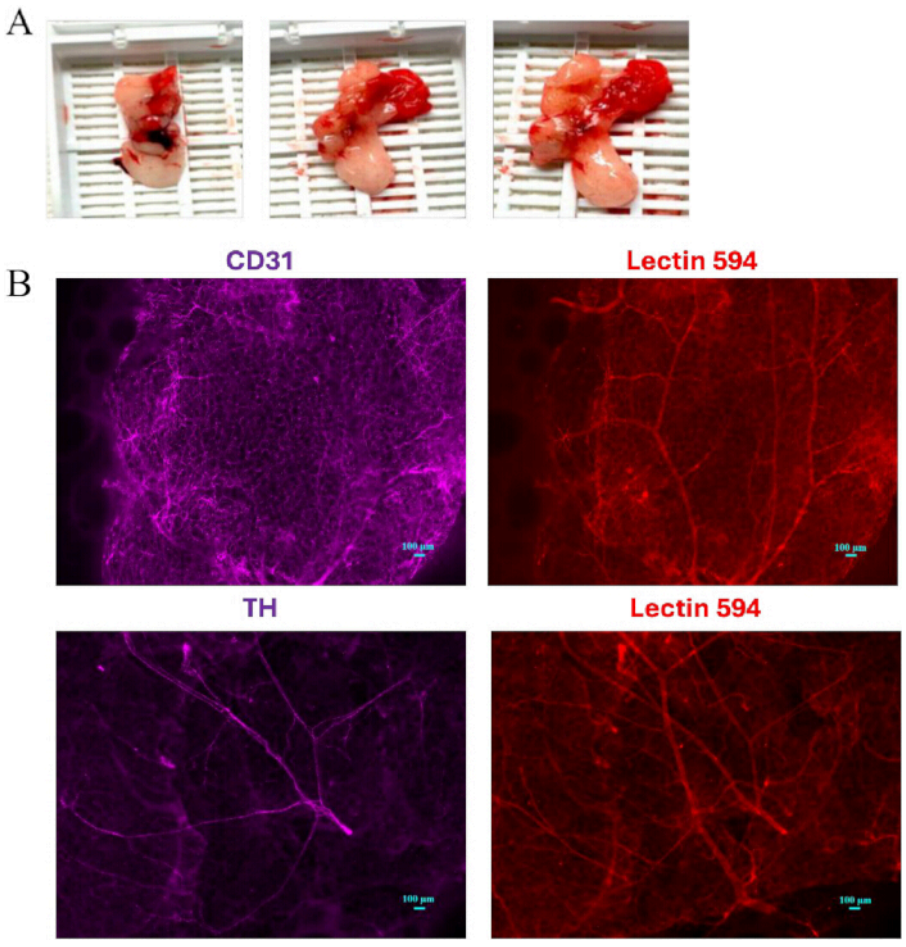

Figure 2: Donor eWAT on postoperative day 2. Representative images of transplanted eWAT collected 2 days after transplantation. (**A**) Representative images of the recovered transplanted tissue at the time of collection. (**B**) Representative images of donor eWAT stained for CD31, Lectin 594, and TH. Please click here to view a larger version of this figure.

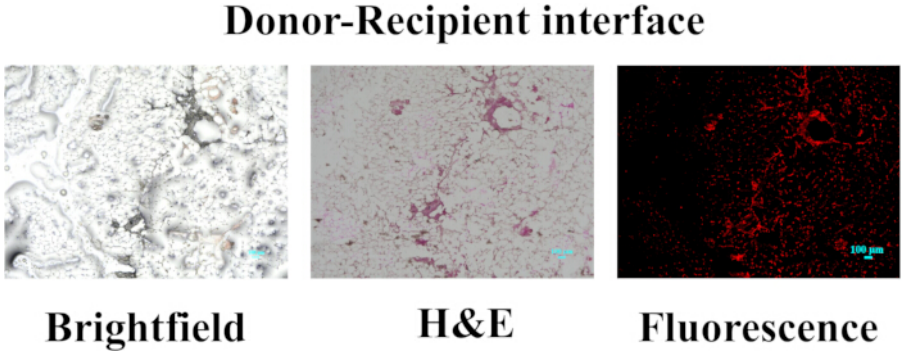

Figure 3: Identification of the donor–recipient interface after appositional white adipose tissue transplantation. Representative brightfield, hematoxylin and eosin (HE), and fluorescence images of the donor–recipient interface. Adipose tissue from mT/mG donor mice expresses membrane-targeted tdTomato fluorescence, allowing the donor graft to be distinguished from the recipient tissue. The images show preservation of graft architecture and close contact between the donor and recipient adipose tissues. Scale bars, 100 µm. Please click here to view a larger version of this figure.

Copyright © 2026, Journal of Visualized Experiments

DOI 10.3791/73227

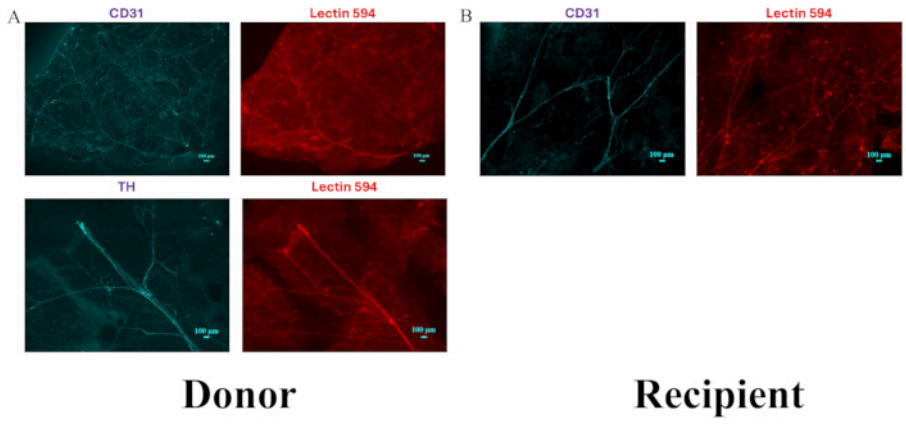

Figure 4: Vascular and TH-positive signals in donor and recipient eWAT at 3 weeks after transplantation. Representative immunofluorescence images of (**A**) transplanted donor eWAT and (**B**) recipient eWAT at 3 weeks after transplantation, stained for CD31, Lectin 594, and TH. Please click here to view a larger version of this figure.

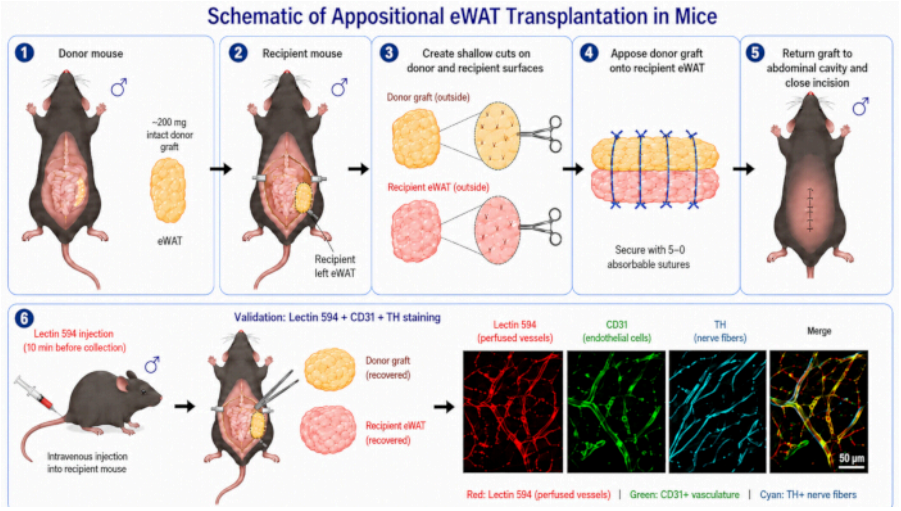

Figure 5: Schematic overview of appositional eWAT transplantation and validation of graft vascularization and innervation. Please click here to view a larger version of this figure.

Discussion

Adipose tissue transplantation is a valuable experimental approach for determining whether a defined adipose depot can influence host physiology. Existing methods, including fat-slice implantation, small-fragment transplantation, and syringe-assisted delivery, offer distinct experimental advantages. For example, slice-based implantation can increase graft surface area and may reduce central ischemia in larger grafts, while small-fragment and syringe-based approaches allow donor tissue to be distributed within a recipient site. The appositional transplantation method described here was developed with a different design strategy. An intact donor adipose graft is positioned directly against a corresponding recipient adipose depot to maintain the graft as a single tissue unit, provide controlled positioning, and establish a defined area of adipose-to-adipose contact. These design features provide a platform for investigating adipose tissue integration, remodeling, and depot-specific effects on host physiology.

A key feature of this method is the use of an intact adipose tissue graft. Adipose tissue is composed of mature adipocytes embedded within a complex microenvironment that includes extracellular matrix, vascular networks, stromal cell populations, and immune cells. Mechanical disruption through mincing, homogenization, or syringe-assisted delivery can alter this organization and damage fragile adipocytes, potentially affecting graft viability, tissue remodeling, and donor-derived biological responses after transplantation. The appositional approach avoids deliberate mincing or homogenization and instead uses

Copyright © 2026, Journal of Visualized Experiments

DOI 10.3791/73227

a defined intact graft of approximately 200 mg. This design is intended to limit mechanical disruption and maintain the structural organization of the donor tissue during transplantation. Maintaining the donor tissue as a single unit may be useful for studies of adipose tissue inflammation, fibrosis, angiogenesis, immune cell organization, and depot-specific signaling, in which the local tissue microenvironment may influence experimental outcomes[1]. Slice-based approaches reduce the size of individual grafts and may improve diffusion into the transplanted tissue, but they also divide the donor depot into multiple tissue pieces[7]. In contrast, the present method maintains the defined graft as a single tissue unit during transplantation. This distinction represents a difference in experimental design rather than a demonstrated advantage over other transplantation approaches.

Another design feature of this approach is preservation of the recipient adipose pad as the local host environment. Rather than implanting donor adipose tissue into an empty pocket or a non-adipose site, the graft is apposed directly to the corresponding endogenous adipose depot. This arrangement establishes direct contact between donor and recipient adipose tissues while maintaining the anatomical organization of the recipient depot. During the procedure, visible vascular structures in epididymal adipose tissue should be preserved, and the thin, sheet-like inguinal white adipose tissue should be handled carefully to avoid drying and mechanical injury.

The use of a relatively small, defined graft does not restrict this model to studies of local tissue biology. Previous adipose transplantation studies have demonstrated that grafts of approximately 200 mg can exert systemic metabolic effects when they harbor a sufficiently strong biological signal. For example, selective activation of GIPR signaling in transplanted gonadal adipose tissue reduced food intake and attenuated long-term weight gain in recipient mice[11]. Similarly, transplantation of adipose tissue with altered macrophage mitochondrial activity has been shown to transfer beneficial or detrimental metabolic phenotypes to recipient animals[12]. Together, these findings demonstrate that localized alterations within a defined adipose graft can influence whole-body physiology, supporting the utility of this transplantation model for investigating both local adipose tissue biology and systemic metabolic regulation.

Functional and structural validation is essential for interpreting the outcomes of this transplantation model. In the present protocol, graft validation combines gross assessment of donor–recipient tissue association with reporter-based frozen-section analysis of the donor–recipient interface, Lectin 594 perfusion, and whole-mount immunofluorescence staining of adipose tissue for CD31 and tyrosine hydroxylase (TH). During the first two days after transplantation, progressive physical association was observed between donor and recipient adipose tissues. Evidence of tissue fusion was apparent by day 1 and became more pronounced by day 2, with progressive broadening of the contact region and loss of a clearly defined tissue boundary. These gross observations are consistent with early and progressive tissue fusion between donor and recipient adipose tissues.

Because gross appearance and suture position alone cannot definitively distinguish donor tissue from recipient tissue, fluorescent reporter donors provide an additional method for validating the interface. In the present study, Rosa26-mT/mG reporter mice were used as donors in separate transplantation experiments. On postoperative day 2, the donor graft and adjacent recipient adipose tissue were collected together as an intact tissue block and analyzed by frozen sectioning. Reporter fluorescence, together with tissue morphology, allowed the donor and recipient regions to be distinguished and the interface to be localized. Subsequent H&E staining of the same sections provided complementary morphological assessment of the interface. Thus, reporter-based frozen-section analysis provides additional validation of donor–recipient tissue assignment beyond gross appearance and suture position.

Histological validation provides information that cannot be obtained through gross examination alone. CD31 staining identifies vascular structures within donor and recipient adipose tissues; however, it does not determine whether these vessels are functionally connected to the recipient circulation. To address this limitation, fluorescent Lectin 594 is administered intravenously prior to tissue collection. Because Lectin 594 labels vessels accessible to the circulating blood, its presence within graft-associated vessel-like structures provides evidence of vascular perfusion through the recipient circulation. Thus, detection of both CD31-positive structures and Lectin 594 signal within the donor graft supports not only the presence of vascular networks but also their perfusion following transplantation.

TH staining provides an additional structural measure of sympathetic nerve fiber presence within the graft. This assessment is important because adipose tissue function is regulated by both vascular supply and sympathetic innervation. Detection of TH-positive fibers within transplanted adipose tissue indicates the presence of sympathetic nerve structures following transplantation. However, TH staining should be interpreted as a structural marker and does not by itself demonstrate functional neural connectivity. In addition, because the whole-mount TH analysis was performed in separate transplantation experiments without fluorescent reporter donors, these data do not determine whether TH-positive fibers within the graft are retained donor fibers or host-derived fibers. Together, CD31 staining, Lectin 594 perfusion, and TH staining provide complementary evidence that transplanted adipose tissue contains vascular networks, is perfused through the recipient circulation, and contains TH-positive sympathetic nerve structures after transplantation[10,13].

Copyright © 2026, Journal of Visualized Experiments

DOI 10.3791/73227

The 3-week time point provides an important assessment of graft preservation and host integration beyond the early stages of tissue fusion. Although gross examination demonstrates rapid physical association between donor and recipient tissues during the first two postoperative days, longer-term evaluation is required to determine whether the transplanted tissue remains viable and functionally connected to the host. At 3 weeks after transplantation, CD31-positive endothelial structures, Lectin 594-positive vessel-like structures, and TH-positive fibers were detected within the donor graft. These findings suggest that the transplanted adipose tissue remains viable, is perfused through the host circulation, and retains sympathetic nerve structures at a later post-transplantation stage. Together, the early gross observations, reporter-based interface validation, and subsequent vascular and neural analyses provide complementary evidence supporting successful graft integration and strengthening the overall interpretation of the appositional transplantation model.

Several technical considerations are important for achieving reproducible results. Donor adipose tissue should be handled gently and transplanted promptly after harvest to minimize ischemic stress. Throughout the procedure, the recipient adipose pad should be protected from drying and contamination. Preparation of the graft-host interface should create a fresh appositional surface while avoiding tissue fragmentation and injury to major blood vessels. Sutures should provide sufficient tension to maintain stable graft contact without excessive compression, as impaired local perfusion may compromise graft viability.

For tissue collection, the donor graft and recipient adipose tissue should initially be harvested together as a single connected tissue block to preserve and verify the graft-host relationship. For reporter-based interface analysis, the intact donor-recipient tissue block is fixed and processed for frozen sectioning without separating the two tissues. In contrast, for the whole-mount vascular and nerve analyses used in the present study, donor and recipient tissues are processed separately. Thus, the reporter-based frozen-section analysis and the whole-mount vascular and neural analyses provide complementary but distinct information. The reporter-based interface analysis also has limitations. The 20-µm frozen sections provide a relatively thin view of the tissue and are less suitable than whole-mount imaging for visualizing extended three-dimensional vascular and nerve fiber structures. We also attempted to identify the reporter-defined donor-recipient interface in whole-mount preparations, but the interface could not be consistently resolved with sufficient clarity. Therefore, the reporter-based frozen-section analysis was used primarily to validate donor–recipient tissue assignment and interface localization.

One limitation of the current neural validation strategy is that TH staining identifies the presence of sympathetic nerve fibers but does not reveal their origin. Because the whole-mount TH analysis was performed without fluorescent reporter donors, the present experiments cannot distinguish whether TH-positive fibers within the donor graft represent retained donor-derived nerves or recipient-derived fibers that have entered the graft following transplantation. Addressing this question will require additional approaches, such as combining donor–recipient lineage labeling with methods that preserve larger three-dimensional tissue structures or using neural tracing studies.

A second limitation relates to the assessment of vascular integration. Although Lectin 594 perfusion provides evidence that graft-associated vessels are connected to the recipient circulation, it does not fully characterize the remodeling process of the graft vasculature. Future studies incorporating additional vascular markers and longitudinal analyses at multiple time points could provide a more detailed understanding of how donor and recipient vascular networks reorganize and integrate following transplantation.

A third limitation is that functional outcomes following adipose tissue transplantation were not assessed in the present study. The current protocol primarily focuses on structural assessment of the donor–recipient interface and graft-associated vascular and neural features. Therefore, the present findings do not establish whether the transplanted adipose tissue produces functional or metabolic changes in the recipient. Future studies incorporating functional and metabolic assessments will be needed to determine the physiological consequences of the transplantation procedure.

An additional limitation of this study is that the transplantation protocol was validated only in male mice. Female-to-female transplantation was not evaluated, and potential sex-dependent differences in graft survival, vascular perfusion, and sympathetic nerve fiber presence therefore remain to be determined.

In summary, appositional adipose tissue transplantation provides an experimental approach for studying intact adipose graft biology in mice. This method is designed to maintain the donor tissue as an intact graft, provide controlled positioning of the graft, and establish direct stable adipose-to-adipose contact with the recipient depot. Early gross examination demonstrates rapid donor–recipient tissue integration within the first two days after transplantation, while reporter-based frozen-section analysis provides additional validation of donor–recipient tissue assignment and interface localization. Complementary analyses using CD31 staining, Lectin 594 perfusion, and TH staining assess vascular structure, functional perfusion, and the presence of sympathetic nerve fibers within the graft. By combining preservation of native tissue architecture with a comprehensive validation strategy, this model provides a versatile platform for investigating adipose tissue remodeling, angiogenesis, innervation, inflammation, fibrosis, depot-specific

Copyright © 2026, Journal of Visualized Experiments

DOI 10.3791/73227

signaling, and potential systemic metabolic effects mediated by genetically or pharmacologically modified adipose tissue[14].

Disclosures

The authors have nothing to disclose.

Acknowledgments

The authors were supported by US NIH grants R01-DK143576, R01-DK55758, R01-DK099110, R01-DK127274, R01-DK131537 to P.E.S., P30-DK127984 to Jay Horton and P.E.S., and P01 AG051459 to Vishwa Dixit and P.E.S.

References

1. Rosen ED, Spiegelman BM. What we talk about when we talk about fat. Cell. 2014;156(1-2):20-44.
2. Kershaw EE, Flier JS. Adipose tissue as an endocrine organ. J Clin Endocrinol Metab. 2004;89(6):2548-2556.
3. Ibrahim MM. Subcutaneous and visceral adipose tissue: structural and functional differences. Obes Rev. 2010;11(1):11-18.
4. Tran TT, Yamamoto Y, Gesta S, Kahn CR. Beneficial effects of subcutaneous fat transplantation on metabolism. Cell Metab. 2008;7(5):410-420.
5. Tran TT, Kahn CR. Transplantation of adipose tissue and stem cells: role in metabolism and disease. Nat Rev Endocrinol. 2010;6(4):195-213.
6. Foster MT et al. Subcutaneous adipose tissue transplantation in diet-induced obese mice attenuates metabolic dysregulation while removal exacerbates it. Physiol Rep. 2013;1(2):e00015.
7. Yeh YS et al. Subcutaneous transplantation of white adipose tissue. Methods Mol Biol. 2023;2662:183-192.
8. Mariano MO et al. White and brown adipose grafts: an approach to correct reproductive, metabolic, and renal deficits in black and tan brachyury (BTBR) obese mice. J Vis Exp. 2025;223:68759.
9. Eto H et al. The fate of adipocytes after nonvascularized fat grafting: evidence of early death and replacement of adipocytes. Plast Reconstr Surg. 2012;129(5):1081-1092.
10. Li X, Mao Z, Yang L, Sun K. Co-staining blood vessels and nerve fibers in adipose tissue. J Vis Exp. 2019;144:59266.
11. Yu X et al. The GIP receptor activates futile calcium cycling in white adipose tissue to increase energy expenditure and drive weight loss in mice. Cell Metab. 2025;37(1):187-204.e7.
12. Joffin N et al. Adipose tissue macrophages exert systemic metabolic control by manipulating local iron concentrations. Nat Metab. 2022;4(11):1474-1494.
13. Lee KY et al. Lessons on conditional gene targeting in mouse adipose tissue. Diabetes. 2013;62(3):864-874.
14. Choe SS et al. Adipose tissue remodeling: its role in energy metabolism and metabolic disorders. Front Endocrinol (Lausanne). 2016;7:30.

Copyright © 2026, Journal of Visualized Experiments